

## Lipolysis of a painful lipoma with ozone: the role of ultrasound in the diagnosis and quantification of the treatment

Dear Editor,

A 31-year-old woman was seen due to a painful mass on the anterolateral side of the right forearm (causing swelling, pain and paresthesia especially during wrist movements) for the last 3 months. On detailed questioning, she reported nonpainful lipomas on the left forearm and abdominal regions. She also declared that she had progressive weight gain in the last year. Her family history was unremarkable other than her mother's having multiple lipomas.

Physical examination showed bilateral subcutaneous mass lesions on both forearms and abdominal regions. Ultrasound imaging showed a lipoma of 3.05 cm × 0.72 cm (cross-sectional area: 1.63 cm<sup>2</sup>) on the painful side (**Figure 1**). Based on the patient's history and physical/imaging findings, she was diagnosed as familial multiple lipomatosis. Accordingly, 10 g (10 mL) of ozone-oxygen mixture was injected into the lipoma under the ultrasound-guidance (**Figure 1A**). The patient's discomfort disappeared immediately after the procedure. One week later, the size of the lipoma resolved dramatically to its one third (1.09 mm × 0.63 mm, 0.61 cm<sup>2</sup>) (**Figure 1B**). Thereafter, an additional dose of 5 g (5 mL) of ozone-oxygen injection was performed. One week later, as the size of the lipoma was unchanged and the patient was asymptomatic, we suggested a follow-up without any additional injection.

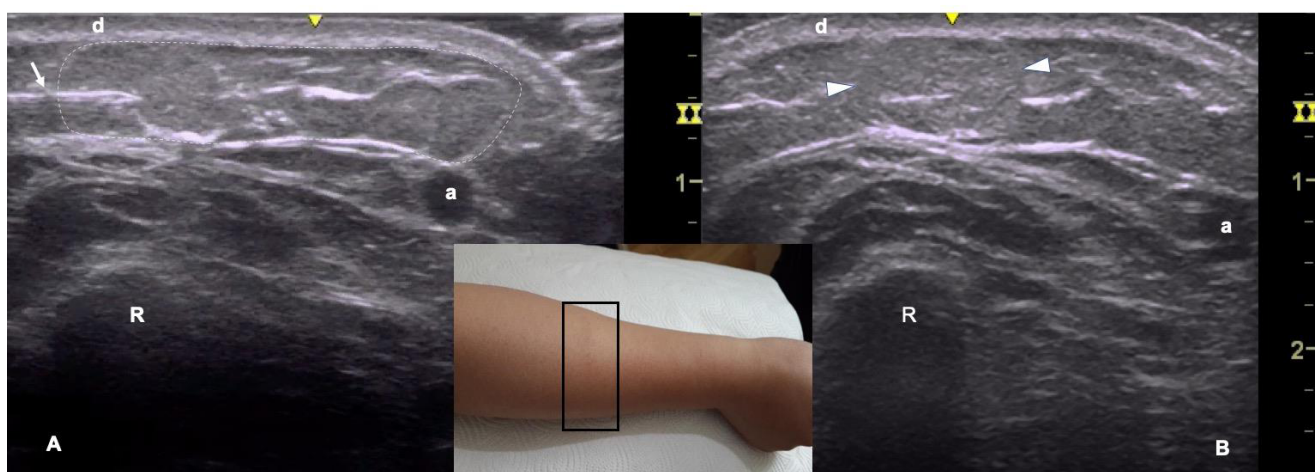
Lipomas are relatively common (about 1% in the general population), slowly growing mesenchymal tumors of mature fat cells, which may extend to deep fascial planes, muscles, bones and joints.<sup>1</sup> Although they usually develop as solitary lesions, about 20% of patients present with multiple lipomas. The etiology remains unknown; but they are often related to disorders of the peripheral nervous system and traumas.

Patients generally request removal of these lipomas due to their concerns about growth, cosmetic reasons, or symptoms secondary to neurovascular compression or inflammation.

Treatment of lipomas generally includes surgical excision and liposuction depending on the size, location, and clinical characteristics. However, these procedures are associated with risks of scarring, seroma, and hematoma formation. Therefore, minimally invasive techniques can be preferred especially for patients with multiple lipomas or for those unwilling to undergo surgical removal. In this regard, several topical lipolytic agents, *e.g.* mixture of ozone-oxygen gas, phosphatidylcholine, deoxycholate, and β<sub>2</sub>-adrenergic agonist (isoproterenol) and corticosteroid combinations, are becoming increasingly popular, which can reduce the size of lipomas about 45% to 75%.<sup>2,3</sup> Interestingly, in a recent study, ultrasound-guidance has been used for removal of fluid accumulation within the lipoma following deoxylate treatment.<sup>4</sup> In that study, a complete removal was seen in about 70% of lipomas, and the remaining lipomas were significantly reduced in size.<sup>4</sup> Further, after the consolidation of treated lipomas are achieved, an easier surgical removal can be performed if required.

Ozone-oxygen therapy can be an effective treatment for lipodystrophies through splitting fatty acids by reducing the chains and making them hydrophilic, the removal of interstitial edema due to cellulite or poor circulation, and also through providing more oxygen which improves local metabolism and venous/lymphatic circulation.<sup>5</sup> Although randomized controlled studies are lacking, in a recent case series of 20 patients with painful lipomas, oxygen-ozone injections reduced the size of lipoma (with a mean reduction of 4 cm) and pain severity (mean visual analogue scale score decreased from 7 to 1) in 10 sessions.<sup>5</sup> In that study, accurate diagnoses of patients' lesions were performed using ultrasound and/or magnetic resonance imaging; however, the size of the lipomas was measured externally with palpation.

Although local lipolytic agents have been found effective in reducing fat deposits and lipomas; some complications such



**Figure 1:** Ultrasound-guided intralesional ozone-oxygen mixture injection (arrow) of a well-bordered hyperechoic lipoma (dashed lines) over the anterolateral forearm (middle figure).

Note: (A, B) The size of the mass decreased significantly from 3.05 cm × 0.72 cm (a cross-sectional area of 1.63 cm<sup>2</sup>) (A) to 1.09 mm × 0.63 mm (a cross-sectional area of 0.61 cm<sup>2</sup>) (arrowheads) after one session of injection (B). a: Radial artery; R: radius; d: dermis.



as necrosis and abscesses have been reported with the application of phosphatidylcholine and deoxycholate.<sup>6,7</sup> Lipolysis after phosphatidylcholine results in an inflammatory reaction/destruction of affected adipose tissue, similar to factitial panniculitis.<sup>8,9</sup> As these agents affect not only fat cells but also adjacent structures (e.g., muscles, tendons, ligaments and nerves) and as evidence-based data regarding the efficacy, safety, dose, session frequency, and possible recurrences of lipodystrophies by local lipolytic agents are lacking, these agents should only be used by qualified and experienced physicians with caution.<sup>10</sup> Last but not least, as seeing and quantifying is better and safer, ultrasound imaging can be a useful method not only for diagnosis, but also for interventions and follow-up.

*The authors certify that they have obtained the appropriate written consent form from the patient.*

### Özgür Kara, Murat Kara\*

Division of Geriatrics, Department of Internal Medicine, Ankara Yenimahalle Education and Research Hospital, Ankara, Turkey (Kara Ö)  
Department of Physical Medicine and Rehabilitation, Hacettepe University Medical School, Ankara, Turkey (Kara M)

\*Correspondence to: Murat Kara, MD, mkaraftr@yahoo.com.

orcid: 0000-0003-0125-4865 (Murat Kara)

doi: 10.4103/2045-9912.267000

**How to cite this article:** Kara Ö, Kara M. Lipolysis of a painful lipoma with ozone: the role of ultrasound in the diagnosis and quantification of the treatment. *Med Gas Res* 2019;9(3):168-169.

**Copyright license agreement:** The Copyright License Agreement has been signed by all authors before publication.

**Plagiarism check:** Checked twice by iThenticate.

**Peer review:** Externally peer reviewed.

**Open access statement:** This is an open access journal, and articles are distributed under the terms of the Creative Commons Attribution-Non-Commercial-ShareAlike 4.0 License, which allows others to remix, tweak, and build upon the work non-commercially, as long as appropriate credit is given and the new creations are licensed under the identical terms.

## REFERENCES

1. Koyuncu EG, Aydingöz Ü, İskender Ö, Kara M, Özçakar L. An incidental periscapular lipoma with marked bone erosion in an elderly woman with contralateral shoulder pain. *PM R*. 2018;10:1292-1293.
2. Redman LM, Moro C, Dobak J, Yu Y, Guillot TS, Greenway FL. Association of beta-2 adrenergic agonist and corticosteroid injection in the treatment of lipomas. *Diabetes Obes Metab*. 2011;13:517-522.
3. Amber KT, Ovadia S, Camacho I. Injection therapy for the management of superficial subcutaneous lipomas. *J Clin Aesthet Dermatol*. 2014;7:46-48.
4. Mlosek RK, Malinowska S, Wozniak W. Lipoma removal using a high-frequency ultrasound-guided injection of a Class III CE-marked device-Empirical findings. *J Cosmet Dermatol*. 2019;18:469-473.
5. Cardoso O, Rossi P, Galoforo A, Collodo G. Ozone therapy in painful lipodystrophies. A preliminary study. *Ozone Ther*. 2018;3:7510.
6. Rotunda AM, Ablon G, Kolodney MS. Lipomas treated with subcutaneous deoxycholate injections. *J Am Acad Dermatol*. 2005;53:973-978.
7. Hasenschwandtner F, Gundermann KJ. Injection lipolysis with phosphatidylcholine and deoxycholate. *Aesthet Surg J*. 2013;33:1071-1072.
8. Bechara FG, Sand M, Hoffmann K, Sand D, Altmeyer P, Stucker M. Fat tissue after lipolysis of lipomas: a histopathological and immunohistochemical study. *J Cutan Pathol*. 2007;34:552-557.
9. Kopera D, Binder B, Toplak H, Kerl H, Cerroni L. Histopathologic changes after intralesional application of phosphatidylcholine for lipoma reduction: report of a case. *Am J Dermatopathol*. 2006;28:331-333.
10. Kopera D, Binder B, Toplak H. Intralesional lipolysis with phosphatidylcholine for the treatment of lipomas: pilot study. *Arch Dermatol*. 2006;142:395-396.

Received: March 22, 2019

Reviewed: April 16, 2019

Accepted: May 30, 2019